



Chronic Cerebrospinal Venous Insufficiency and Menière's Disease: Interventional Versus Medical Therapy

Giuseppe Attanasio, MD, PhD; Luigi Califano, MD; Aldo Bruno, MD; Vincenzo Giugliano, MD; Massimo Ralli, MD, PhD ; Salvatore Martellucci, MD ; Claudia Milella, MD; Marco de Vincentiis, MD; Francesca Y. Russo, MD, PhD ; Antonio Greco, MD

Objectives/Hypothesis: To evaluate the incidence of chronic cerebrospinal venous insufficiency in Menière's disease patients and the effect of bilateral percutaneous transluminal angioplasty of the jugular/azygos veins compared to medical therapy.

Study Design: Prospective case-control study.

Methods: Five hundred fourteen subjects were included in the study, 412 affected by definite Menière's disease, and 102 healthy controls. All patients underwent audiovestibular and vascular examination. Patients with Menière's disease and concomitant cerebrospinal venous insufficiency were divided in two subgroups: patients who underwent vascular intervention with bilateral percutaneous transluminal angioplasty (PTA) of the jugular/azygos veins and patients treated with medical therapy.

Results: Chronic cerebrospinal venous insufficiency was diagnosed in 330/412 (80.1%) Menière's disease patients and in 12/102 healthy individuals (11.8%) ($P < .001$). In the two chronic cerebrospinal venous insufficiency subgroups, a significant difference in Dizziness Handicap Inventory scores was found between patients in the PTA group compared to patients treated with medical therapy (31 ± 8.6 vs. 48.1 ± 14.4 ; $P < .001$); no significant differences were found for the Tinnitus Handicap Inventory scores (50.8 ± 16.58 vs. 49.6 ± 17.5 ; $P = .23$). Subjective evaluation of aural fullness was significantly better in patients in the PTA group ($P = .003$) as well as pure-tone average, which was significantly different between groups (49.8 ± 16.5 dB in the PTA group vs. 55.8 ± 13 in the medical therapy group; $P = .035$).

Conclusions: The results of the present study confirm the close relationship between vascular disorders and Menière's disease. The encouraging responses to vascular interventional therapy on Menière's disease symptoms suggest that this may be a promising path for interpretation and treatment of this complex disease.

Key Words: Menière disease, vertigo, blood circulation, hypertension, ecography, inner ear.

Level of Evidence: 2b

Laryngoscope, 00:1-7, 2019

INTRODUCTION

Menière disease (MD)¹ is a chronic inner ear disease characterized by the presence of endolymphatic hydrops (EH) and clinically denoted by the presence of four symptoms: mono- or bilateral hearing loss, tinnitus, aural fullness, and acute recurrent dizziness. MD diagnosis is based on the criteria of the Barany Society.² EH appears to be the pathological substrate necessary, but is not sufficient to cause a clinically evident disease. However, to date it

has not been demonstrated that EH is responsible for the entire cochlear and vestibular symptomatology.³⁻¹³

The disease often begins unilaterally but may involve the contralateral ear in a certain percentage of cases, with a progressive increase over the years.¹⁴⁻¹⁹ There is no evidence of efficacious medical therapy in the treatment of the MD, despite the many proposed drugs or techniques.^{20,21} Intratympanic therapies with steroid or gentamicin showed some evidence of efficacy; surgical therapy is currently indicated only for cases unresponsive to medical therapy.²²⁻²⁶

The physiopathology of MD is still controversial. Godlowski²⁷ hypothesized that the elevation of the hydrostatic pressure at the arterial end of the microcirculation in the stria vascularis may increase the force that drives fluid from the capillaries into the endolymphatic space. In such an event, the hydrostatic pressure within the endolymph rises only if the fluid is not eliminated at an equal rate back into the blood at the venous end of the stria vascularis, which finally drains into the internal jugular vein (IJV). Other authors have suggested that alterations in the inner ear venous drainage may promote EH.²⁸⁻³²

In 2006, Zamboni described five ultrasound parameters that assess both anatomic and functional alterations of the neck venous blood flow, which amount to the

From the Head and Neck Department (G.A.), Umberto I Policlinic of Rome, Rome, Italy; Departmental Unit of Audiology and Phoniatrics (L.C., C.M.), G. Rummo Hospital Group, Benevento, Italy; Vascular Surgery Division (A.B.), GEPOS Clinic, Telesse Terme, Italy; Radiology Department (V.G.), GEPOS Clinic, Telesse Terme, Italy; Department of Oral and Maxillofacial Surgery (M.R., M.D.V.), Sapienza University of Rome, Rome, Italy; and the Department of Sense Organs and Ear, Nose, and Throat Department (S.M., F.Y.R., A.G.), Sapienza University of Rome, Rome, Italy.

Editor's Note: This Manuscript was accepted for publication on October 15, 2019.

The authors have no funding, financial relationships, or conflicts of interest to disclose.

Send correspondence to Francesca Yoshie Russo, MD, PhD, Department of Sense Organs, Sapienza University of Rome, Viale del Policlinico 155, Rome, Italy. E-mail: francescayoshie.russo@uniroma1.it

clinical picture of chronic cerebrospinal venous insufficiency (CCSVI).³³ CCSVI has been described as a chronic vascular condition characterized by restricted venous outflow from the brain and spinal cord, mainly due to narrowing or blockage of the veins in the head and neck. This condition may lead to substitute circles, venous reflux, and deposition of iron in the central nervous system, and is diagnosed if a patient presents at least two of the five parameters described by Zamboni.³³ In 2009, CCSVI was identified as a unique venous disease by the Consensus Document of the International Union of Phlebology on Venous Malformations,^{34,35} and in the same year Zamboni et al. proposed an endovascular treatment of the CCSVI lesions through percutaneous transluminal angioplasty (PTA).³⁶

CCSVI may represent a predisposing factor for developing inner ear disorders such as MD. Based upon both the anatomy of venous inner ear drainage, an excess of endolymphatic fluids could be secondary to a chronic reduced or altered venous drainage of the anterior and posterior vestibular veins, and/or of the cochlear veins into the venous cerebrospinal system.³⁷ Data obtained from recent studies seem to support the possible relationship between CCSVI and MD.^{38–43}

The aims of this study were 1) to evaluate the incidence of CCSVI in MD compared to that of CCSVI in a healthy control group; and 2) in patients affected by MD and CCSVI, to evaluate the effects of bilateral PTA of the jugular/azygos veins (AVs) on CCSVI anatomic and functional lesions and evaluate the effects of bilateral PTA of the jugular/AVs on MD symptoms compared to medical therapy.

MATERIALS AND METHODS

Five hundred fourteen subjects were included in the study. The study group included 412 nonconsecutive patients presenting to the otolaryngology department's audiology unit of our university between April 2013 and June 2017 with a diagnosis of definite MD. The control group included 102 healthy volunteers without neurologic or audiovestibular diseases. All 514 patients underwent audiovestibular and vascular examination.

Patients with concomitant MD and CCSVI were divided in two subgroups: patients who underwent vascular intervention with venography of the IJVs and AVs and bilateral PTA of the jugular/AVs (PTA group), and patients treated with medical therapy consisting of betahistine plus heparinoid (medical therapy group). Each patient could choose between the two proposed treatment options.

All of the 514 patients were asked to continue to follow the directions related to the limited consumption of substances such as caffeine, alcohol, tobacco, and sodium. Patients' demographics and characteristics are shown in Table I.

This experimental study was approved by the ethics committee of the Italian National Health Service, Comitato Etico Campania Nord, and was performed according to the Declaration of Helsinki.

Audiological Examination

Patients underwent an anamnestic interview, with special attention to the number of acute vertigo episodes during the previous 6 months, a full ear, nose and throat examination, audiological tests with pure-tone audiometry at the frequency range 500 to 3,000Hz,

TABLE I.
Clinical Characteristics of Patients With Concomitant Menière's disease and Chronic Cerebrospinal Venous Insufficiency Before Intervention.

Patients, n = 330	PTA, n = 134	Medical Therapy, n = 196	P Value
Age, yr	47.4 ± 11.43	47.2 ± 7.81	.45
Disease duration, yr	0.5–28	0.2–25	.48
Pure-tone audiometry, dB HL	57.9	54.8	.48
THI	50.2	52.4	.65
DHI	54.6	55.04	.93

DHI = Dizziness Handicap Inventory; PTA = percutaneous transluminal angioplasty; THI = Tinnitus Handicap Inventory.

acoustic immittance test, and complete vestibular examination. Subjects completed the Italian versions of the Dizziness Handicap Inventory (DHI)⁴⁴ and the Tinnitus Handicap Inventory (THI).⁴⁵ MD was diagnosed according to the 1995 American Academy of Otolaryngology–Head and Neck Surgery Foundation criteria.³

Vascular Examination

All patients underwent duplex ultrasound of the neck veins and intracranial venous circulation according to the 2011 International Society for Neurovascular Disease Consensus criteria³⁴ and modified by guidelines published in 2014.⁴⁶ To reduce bias, a single expert ultrasonographer performed all duplex ultrasound evaluations. The morphology of the IJVs was assessed by means of high-resolution B-mode ultrasound equipped with 2.5 and 7.5 to 10 MHz probes and quality Doppler profile system (QDP) and hemodynamics. Septa/valve malformations and membranes able to influence the venous hemodynamics of cerebral veins in these patients were considered significant venous anatomical abnormalities.⁴⁷

CCSVI was diagnosed when two or more criteria of the Zamboni diagnostic criteria were found (Table II). Intraobserver variability was calculated, aiming to measure the reproducibility of ultrasound evaluations, and its value of 0.89 according to the intraclass correlation coefficient was classified as good if >0.80.

Vascular Intervention

The main criterion adopted to define stenosis of the IJV or AV at venography was at least 50% stenosis of the vein compared with the diameter of an adjacent segment of the vein. Stenosis was confirmed if two of the following additional criteria were met: 1) emptying time of 4 to 6 seconds in all vein projections, 2) intraluminal abnormalities (e.g., web, septa, valvular abnormalities), and 3) collateral veins with a faster emptying time compared with IJV or AV.

The following PTA protocol was applied: percutaneous right/left femoral access under local anesthesia; administration of 2,500 IU of heparin sodium; selective venography of the IJV and AV in three views using a 100-cm4-FBER 2 hydrophilic catheter for the IJV and a 100-cm4-F Cobra catheter for the AV mounted on a 0.035-inch hydrophilic guide wire (Cordis, Miami Lakes, FL). Drainage time of the IJV and AV was evaluated. Dilation was performed with a low-compliance PTA catheter and a 10- to 20-mm balloon (MaxiLD; Cordis) for the IJV and a 10- to 12-mm balloon (MaxiLD; Cordis) for the AV using inflations assisted by an inflation device for 120 seconds at 4 to 8 atm. At discharge, low-molecular-weight heparin was prescribed at a therapeutic dosage (6,000 IU twice daily) for 20 days, followed by mesoglycan at a dosage of 100 mg/d for 12 to 24 months.

TABLE II.
Zamboni Diagnostic Parameters for CCSVI.*

1. Reflux in the IJVs and/or VVs in orthostatic and supine postures	Pathological when reversal flow lasted >0.88 seconds
2. Bidirectional flow (or reflux) in the intracranial veins and sinuses	Using the same intracranial approach and QDP system
3. B-mode abnormalities/stenosis of the IJVs including:	
A. Morphological stenosis	Presence of severe reduction of the CSA of IJVs in the supine position (<0.3 cm ²), which does not increase with Valsalva maneuver
B. Hemodynamic stenosis	Significant stenosis with simultaneous presence of intraluminal defects such as webs, septa, or malformed valves, and hemodynamic changes (block, reflux, increased velocity flow)
4. Flow not Doppler—detectable in IJVs and/or VVs despite numerous forced inspirations	Tested in both sitting and supine position
5. Negative Δ cross-sectional area in the IJV	Value is obtained by measuring the difference in IJV cross-sectional area between the supine and upright positions.

*CCSVI was diagnosed when two or more criteria were found.
CCSVI = chronic cerebrospinal venous insufficiency; CSA = cross-sectional area; IJVs = internal jugular veins; QDP = quality Doppler profile; VVs = vertebral veins.

Follow-up

A 24-month follow-up was considered the end point of the study according to the American Academy of Otolaryngology criteria.³ Twenty-four months after initial diagnosis, patients underwent a new audiovestibular examination. Based on their level of vertigo control, patients were included in one of the A to F classes of control of

vertigo,³ using the ratio between the number of spells of vertigo in the 6 months before the therapy and in the 18- to 24-month period after the therapy. Outcomes were grouped as positive outcome (class A–B) or negative outcome (class C–F). Posttherapy pure-tone averages were compared with pretherapy pure-tone averages. Aural fullness was subjectively evaluated (disappeared, improved, unmodified, and worsened). Patients in the medical therapy group were invited to fill in a diary reporting the regular intake of the therapy.

Patients in the PTA group underwent duplex ultrasound of the neck veins and intracranial venous circulation to evaluate the effects of PTA on CCSVI. Resolution or marked improvement (>80%) of vein stenosis, normal outflow, and disappearance of collateral venous circulation were considered signs of successful PTA.

Statistical Analysis

Demographic data were analyzed by *t* test. A Fisher exact test was used to evaluate the association between CCSVI and definite MD when compared to the control population, aural fullness, and the effects on vertigo spells. Comparison between pre- and posttherapy audiological staging was performed through a χ^2 test. An unpaired *t* test was used to compare pretherapy DHI and THI values in PTA patients versus medical therapy patients, pre- versus posttherapy DHI and THI values, and pre- versus posttherapy pure-tone averages. The outcome of the alterations determining the diagnosis of CCSVI before PTA and at 24 months was also analyzed by Fisher exact test as follows: favorable outcome = absence of venous lesions, unfavorable outcome = persistence of venous lesions. IBM SPSS Statistics for Windows version 20 (IBM, Armonk, NY) was used to analyze the data.

RESULTS

Within the MD study group, unilateral disease was found in 320/412 patients (77.8%), whereas 92/412 had bilateral MD (22.2%); 217 were female (52.5%) and 195 were

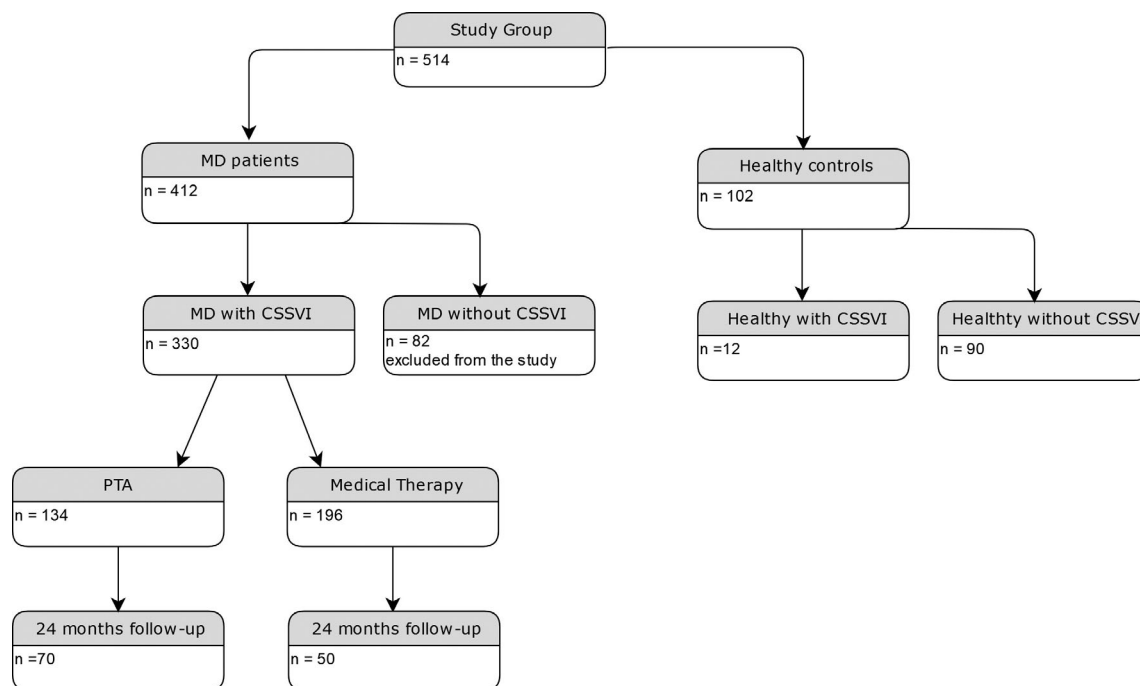


Fig. 1. Flowchart of the study group. CCSVI = chronic cerebrospinal venous insufficiency; MD = Menière's disease; PTA = percutaneous transluminal angioplasty.

TABLE III.
Parameters Evaluated During Vascular Examination and Comparison Between CCSVI-Positive Patients With and Without MD.

	CCSVI-Positive Healthy Controls: 12/102 (12.7%)	CCSVI-Positive MD Patients: 330/412 (80%)
Parameter 1: IJVs and/or VVs reflux	7/12 (58.3%)	147/330 (44.5%)
Parameter 2: Intracranial veins reflux	10/12 (83.3%)	264/330 (80%)
Parameter 3: IJVs stenosis		
A. Morphological	11/12 (91.7%)	297/330 (90%)
B. Hemodynamic	5/12 (41.7%)	230/330 (69.7%)
Parameter 4: Cervical veins blocked outflow	0%	147/330 (44.5%)
Parameter 5: ΔCSA	0%	10/330 (3.3%)

CCSVI = chronic cerebrospinal venous insufficiency; CSA = cross-sectional area; IJVs = internal jugular veins; MD = Menière's disease; VVs = vertebral veins.

male (47.5%). The mean age was 44 ± 22.3 years (range, 34–76 years). The onset of MD ranged from 28 years to 6 months prior to inclusion in the study. In the control group, 54 were female (52.9%) and 48 male (47.1%), and the mean age was 49.3 ± 7.8 years.

CCSVI was diagnosed according to the Zamboni criteria in 330/412 (80.1%) MD patients and in 12/102 healthy individuals (11.8%); no significant differences in mean age and sex were found between CCSVI+ and CCSVI– patients. A significant difference in CCSVI incidence was found between MD patients and the control group ($P < .001$).

In patients with concomitant MD and CCSVI, 134/330 patients (40.6%) underwent bilateral PTA of jugular/AVs and 196/330 patients (59.4%) were treated with medical conservative therapy. Among patients who underwent vascular intervention, 95 had unilateral MD, 39 bilateral MD, 64 were male, and 70 were female. The mean age was 47.4 ± 11.43 years. Among patients treated with medical therapy, 141 had unilateral MD, 55 bilateral MD, 101 were male, and 95 were female. The mean age was 47.2 ± 7.81 years. There was no significant difference between the PTA group and medical therapy group for age ($P = .45$), duration of disease (range, 6 months–28 years and 3 months–25 years, respectively), initial pure tone threshold audiometry (57.9 vs. 54.8 dB HL; $P = .48$), initial THI (50.2 vs. 52.4; $P = .65$), and

initial DHI (54.6 vs. 55.04; $P = .93$) (Table I). A flowchart of the study protocol is shown in Figure 1.

Characteristics of CCSVI Lesions

CCSVI lesions were always bilateral, both in unilateral MD and in bilateral MD. In unilateral MD patients, the affected side presented either a higher number of positive parameters and/or the narrowest lesions. In bilateral MD cases, the higher number of positive parameters and/or the narrowest lesions were on the side initially diagnosed with MD. JVs were involved in 100% of cases, of which only two cases were unilateral. AV involvement, observed during venography, was present in 35 patients (13.1%). Table III shows the diagnostic parameters found at duplex ultrasound evaluation. There were no major complications; minor complications (short-term fibrosis of the jugular vein and an inguinal hematoma) occurred in two patients.

Effects of Vascular Intervention on CCSVI Anatomic and Functional Lesions

To date, 120 patients reached the 24-month follow-up, 70 in the PTA group and 50 in the medical conservative therapy group. In the PTA group, ultrasound on CCSVI lesions showed anatomical and functional restoration of normal flow in 60 patients (85.7%), venous restenosis in 6/70 patients (8.7%), and unmodified lesions in four patients (5.6%).

Effects of Vascular Intervention on MD and Comparison With Medical Therapy

In patients in the PTA group, DHI scores were reduced from 54.62 ± 17.39 to 31 ± 8.6 ($P < .001$) and THI from 50.2 ± 17.4 to 43.5 ± 18.06 ($P = .24$). Additionally, 49/70 patients (70%) reported an improvement in aural fullness, 21/70 (30%) were unchanged, and no cases worsened. The pure-tone average changed from 52.9 ± 17.19 dB HL to 49.8 ± 16.58 dB HL ($P = .22$) (Table IV). Medical history evaluation of acute dizziness episodes occurring between 18 and 24 months after PTA showed good control of vertigo (class A–B) in 57/70 patients (81.4%) (class A: 25 patients, class B: 32 patients), limited control (class C) in 10/70 patients (14.2%), and worsening in three patients (4.2%), two in class E, one in class F.

TABLE IV.
Outcomes in Patients With concomitant MD and Chronic Cerebrospinal Venous Insufficiency Treated With PTA or Medical Therapy 24 Months After Intervention or Medical Treatment.

	MD and PTA (70 Patients)			MD and Medical Therapy (50 Patients)		
	Pretherapy	Posttherapy	P Value	Pretherapy	Posttherapy	P Value
DHI	54.6 ± 17.3	31 ± 8.6	.001*	55 ± 17.8	48.1 ± 14.4	.1
THI	50.2 ± 17.4	43.5 ± 18.1	.24	52.4 ± 16.6	49.6 ± 17.5	.54
Pure-tone audiometry, dB	52.9 ± 17.1	49.8 ± 16.5	.22	49.8 ± 16.5	55.8 ± 13	.09

*Statistically significant.

DHI = Dizziness Handicap Inventory; MD = Menière's disease; PTA = percutaneous transluminal angioplasty; THI = Tinnitus Handicap Inventory.

TABLE V.

Differences Between Patients With Concomitant MD and Chronic Cerebrospinal Venous Insufficiency Treated With PTA or Medical Therapy for Vertigo, Tinnitus, Pure-Tone Audiometry, and Fullness 24 Months After Intervention or Medical Treatment.

	MD and PTA (70 Patients)	MD and Medical Therapy (50 Patients)	P Value
DHI	-23.6	-6.94	<.001*
THI	-6.7	-2.8	.23
Pure-tone audiometry, dB	-7.1	+6	.009*
Vertigo class			.03*
A + B	57 (81.4%)	31 (62%)	
C + D	10 (14.2%)	7 (14%)	
E	2 (2.8%)	1 (2%)	
F	1 (1.4%)	9 (18%)	
Fullness			.003*
Improved	49 (70%)	9 (18%)	
Unchanged	21 (30%)	24 (48%)	
Worsened	0	17 (34%)	
Absent	0	0	

*Statistically significant.

DHI = Dizziness Handicap Inventory; MD = Menière's disease; PTA = percutaneous transluminal angioplasty; THI = Tinnitus Handicap Inventory.

In patients in the conservative medical treatment group, DHI scores were reduced from 55.04 ± 17.82 to 48.1 ± 14.4 ($P < .1$) and THI scores from 52.4 ± 16.6 to 49.6 ± 17.5 ($P = .54$). Additionally, 9/50 patients (18%) reported an improvement in aural fullness, 24/50 (48%) were unchanged, and 17/50 patients (34%) worsened. Pure-tone audiometry changed from 49.8 ± 16.65 dB HL to 55.79 ± 13.09 ($P = .09$) (Table IV). The evaluation of acute dizziness episodes between 18 and 24 months after PTA showed good control of vertigo (class A–B) in 31/50 patients (62%) (class A: 10 patients, class B: 21 patients), limited control (class C) in 7/50 patients (14%) and two patients with class D, and worsening in 10 patients, one in class E and nine in class F.

A significant difference in DHI score was found between patients in the PTA group compared to patients treated with medical therapy (31 ± 8.6 vs. 48.1 ± 14.4 ; $P < .001$); no significant differences were found for THI (50.8 ± 16.58 vs. 49.6 ± 17.5 ; $P = .23$). Subjective evaluation of aural fullness was significantly better in patients in the PTA group ($P = .003$), and pure-tone average was significantly different between groups (49.8 ± 16.58 dB in the PTA group vs. 55.8 ± 13.09 in the medical therapy group; $P = .035$). More patients in the PTA group were classes A and B versus classes C to F for acute vertigo crisis control ($P = .04$) (Table V).

DISCUSSION

In the present study, ultrasound-diagnosed CCSVI has an incidence of 80.1% in MD patients and 11.8% in the control group, confirming the possible relationship

between MD and CCSVI. The two main positive parameters were IJV stenosis (91.7%) and intracranial venous reflux (83.3%), similar to a previously published trial.³⁹

The results of PTA in MD patients show that the improvement of venous outflow was particularly effective in controlling the vertigo symptoms. Twenty-four months after the intervention, 83.3% of MD patients reached class A or B, compared to 53% of the patients who underwent medical therapy. The difference between the two subgroups was significant, as well as for the pure-tone audiometry before and after the therapy and the DHI score. None of the patients reported a significant improvement of the tinnitus symptom, whereas subjective ear fullness was improved in 70% of the patients who underwent PTA compared to 16.7% of the patients treated by medical therapy only. We can therefore highlight a significant improvement of symptoms concurrently with the improvement of venous drainage of the inner ear, despite the necessity to analyze the data of the other patients who, to date, have not yet reached the end of the follow-up.

In 2006, Zamboni described the syndrome defined CCSVI, initially associated with multiple sclerosis, raising a debate in the scientific community.³³ The anatomical and functional alterations typical of CCSVI have raised the issue of whether this condition could contribute to determining alterations in the inner ear, especially in an area with a high degree of vascularization such as the stria vascularis, of which significant alterations have been described in patients suffering from MD.²⁵

In 2007, Friis and Klaus²⁸ banded the vestibular aqueduct vein of mice and induced symptoms similar to those of MD. This might be due to the direction of the venous flow in the inner ear that would reverse, leading to a portal-like circulation, in which the venous capillary blood goes back into the arterial capillary circulation, thus leading to a modification of the endolymph flow but also influencing the function of nonreceptorial structures involved in endolymph metabolism. In addition, the endolymphatic sac, as it was described in several studies, contains glycosaminoglycans, proteins, and a natriuretic hormone, whose modifications would result in changes in the composition of the inner ear fluids with negative functional effects on dark cells.^{31,48,49} Moreover, thrombotic obstruction of the vestibular vein of the aqueduct has been demonstrated in some patients with MD on histopathologic examination; the presence of microthrombi can modify the dynamics of the flow, which could explain the fluctuation of symptoms typical of MD.^{29,50} Over the years, the persistence of a slow outflow, with subsequent lesions affecting the endothelium of the labyrinth veins, could induce fibrosis of the sac and endolymphatic duct, decrease vascularization of these structures, and increase local hydrostatic pressure, until inversion of the venous flow, as previously seen in the experimental model of Friis and Klaus.²⁸

Merchant et al.'s model demonstrated the constant presence of EH in MD patients, but not the noncontextual presence of MD in all cases with EH.³⁷ They hypothesized that EH may be a symptom and not the cause of MD, and is itself due to a prior modification of labyrinth homeostasis caused by a cellular toxicity phenomena of type I and

type II fibrocytes involved in the homeostasis of endolabyrinthic fluids. The alterations described in the brain could also affect the structures of the inner ear, which also drain into the jugular venous system. In particular, according to the Merchant et al. model, the site of greatest interest should be the stria vascularis, with its type I and II fibrocytes actively involved in endolymph homeostasis. We could expect that at least one of the unknown causes of toxicity postulated by Merchant et al. is venous stasis with consequent cell damage to the stria vascularis, which would result in alterations of metabolism and homeostasis leading to the secondary development of hydrops.

In the inner ear, the slowed venous outflow that occurs in CCSVI would affect the venous wall, increasing its permeability with formation of perivenular lymphocytic infiltrates and deposition of iron. This condition, especially in a highly vascularized district such as stria vascularis, would cause cytotoxic damage of the fibrocytes, activating the sequence of events described above.

The uncertainty about the etiology of MD has determined an extreme variability in the therapeutic approach to this disease, and to date, there is no conservative medical therapy available that guarantees the control of the disease. The therapy with betahistidine, which is mostly used in Europe, has proved to be essentially ineffective in a very recent randomized study.⁵¹

The improvement of the anatomical and functional alterations of the jugular venous circle obtained in CCSVI after PTA seems to have had a positive effect in patients with defined MD. In particular, during the 2-year follow-up, approximately 85% of patients entered in class A or B regarding control of acute vertigo crisis with statistical significance compared to the group treated with medical therapy. The other symptom that responded very positively to treatment was auricular fullness, and the results were less positive for tinnitus, for which no significant differences were found in either group. However, a concern that may arise from the use of this particular technique is the absence of a valid method for quantifying the venous outflow before and after PTA,⁵² probably due to different IJV luminal defects responding differently to PTA, therefore leading to different hemodynamic results, which may explain why some patients with MD have not reported an improvement following PTA.

The assessment of auditory responses is more complex. The threshold difference assessed with pure-tone audiometry pre- and posttherapy at 24 months did not show a significant change, but there was a tendency for improvement of the hearing threshold. The group treated with medical treatment also showed a nonsignificant difference in audiometry pre- and post-therapy; however, a tendency to worsen the threshold was observed. As a consequence, although there was no significant difference between the two groups in the values of pure-tone audiometry before intervention, the posttreatment values at 24 months were significantly different ($P < .009$).

A weakness of the present study is the lack of an objective assessment of inner ear status at the inclusion phase and at the last follow-up, for example by means of

electrocochleography. The diagnosis of MD was defined only by clinical parameters as recommended by the American Academy of Otolaryngology–Head and Neck Surgery Foundation, and we retrospectively collected the subjective data concerning vertigo, tinnitus, and aural fullness. However the American Academy of Otolaryngology–Head and Neck Surgery Foundation considers the clinical criteria as sufficient to diagnose and follow the evolution of MD. Furthermore, we could consider an objective vestibular evaluation to estimate the effects on the vestibular system. However, due to the fluctuation of symptoms, we preferred to collect the data regarding the clinical symptoms of the patients, as is performed by most physicians who follow these patients.

The patient's quality of life, assessed with DHI, showed a significant improvement in the group subjected to PTA both compared to the initial values of the same group and to the posttherapy values of the group treated with medical therapy.

CONCLUSION

The results of the present study confirm the close relationship between vascular disorders and MD, which is also highlighted by encouraging responses to interventional therapy. The ethical and feasibility limits remain a reason for discussion and comparison between otologists, but the results justify the interest in these new procedures, considering that medical care in general in MD probably has a positive effect. Other experimental studies are needed in this field, which can be one of the promising paths for the interpretation and treatment of this complex disease.

BIBLIOGRAPHY

1. Ménière P. Pathologie auriculaire: mémoires sur des lésions de l'oreille interne donnant lieu à des symptômes de congestion cérébrale aploplectiforme. *Gaz Med Paris* 1861;16:597–601.
2. Lopez-Escamez JA, Carey J, Chung W-H, Joel A. et al. Diagnostic criteria for Ménière's disease. *J Vestib Res* 2015;25:1–7.
3. Committee on Hearing and Equilibrium guidelines for the diagnosis and evaluation of therapy in Meniere's disease. American Academy of Otolaryngology-Head and Neck Foundation, Inc. *Otolaryngol Head Neck Surg* 1995;113:181–185.
4. Louza J, Krause E, Gürkov R. Hearing function after intratympanic application of gadolinium-based contrast agent: a long-term evaluation. *Laryngoscope* 2015;125:2366–2370.
5. Casselman JW, Kuhweide R, Ampe W, Meeus L, Steyaert L. Pathology of the membranous labyrinth: comparison of T1- and T2-weighted and gadolinium-enhanced spin-echo and 3DFTCISS imaging. *AJNR Am J Neuroradiol* 1993;14:59–69.
6. Albers FW, Van Weissenbruch R, Casselman JW. 3DFT-magnetic resonance imaging of the inner ear in Ménière's disease. *Acta Otolaryngol* 1994;114:595–600.
7. Nakashima T, Naganawa S, Sugiura M, et al. Visualization of endolymphatic hydrops in patients with Ménière's disease. *Laryngoscope* 2007;117:415–420.
8. Naganawa S, Sugiura M, Kawamura M, Fukatsu H, Sone M, Nakashima T. Imaging of endolymphatic and perilymphatic fluid at 3T after intratympanic administration of gadolinium-diethylene-triamine pentaacetic acid. *AJNR Am J Neuroradiol* 2008;29:724–726.
9. Wu Q, Dai C, Zhao M, Sha Y. The correlation between symptoms of definite Ménière's disease and endolymphatic hydrops visualized by magnetic resonance imaging. *Laryngoscope* 2016;126:974–979.
10. Schuknecht HF, Gulya AJ. Endolymphatic hydrops—an overview and classification. *Ann Otol Rhinol Laryngol* 1983;92:1–20.
11. Sperling NM, Paparella MM, Yoon TH, Zeltzman D. Symptomatic versus asymptomatic endolymphatic hydrops: a histopathologic comparison. *Laryngoscope* 1993;103:277–285.

12. Kiang NYS. An auditory physiologist's view of Ménière's syndrome. In: Nadol JB Jr, ed. *Second International Symposium on Ménière's Disease*. Amsterdam, the Netherlands: Kugler and Ghedini; 1989:13–24.
13. Nadol JB Jr, ed. *Second International Symposium on Ménière's Disease*. Amsterdam, the Netherlands: Kugler and Ghedini; 1989.
14. Ohmen JD, White CH, Li X, et al. Genetic evidence for an ethnic diversity in the susceptibility to Ménière's disease. *Otol Neurotol* 2013;34:1336–1341.
15. Belinchon A, Perez-Garrigues H, Tenias JM. Evolution of symptoms in Ménière's disease. *Audiol Neurootol* 2012;17:126–132.
16. Seo T, Saka N, Sakagami M. Furosemide-loading vestibular evoked myogenic potential testing can suggest developing bilateral involvement of unilateral Meniere's disease. *Acta Otolaryngol* 2012;132:632–636.
17. Friberg U, Stahle J, Svedberg A. The natural course of the Ménière's disease. *Acta Otolaryngol Suppl* 1984;406:72–77.
18. Havia M, Kentala E. Progression of symptoms of dizziness in Ménière's disease. *Arch Otolaryngol Head Neck Surg* 2004;130:431–435.
19. Tokumasu K, Fujino A, Yoshio S, Hoshino I. Prognosis of Ménière's disease by conservative treatment: retrospective study on the time course of the disease. *Acta Otolaryngol Suppl* 1995;519:216–218.
20. Liu YF, Renk E, Rauch SD, Xu HX. Efficacy of intratympanic gentamicin in Ménière's disease with and without migraine. *Otol Neurotol* 2017;38:1005–1009.
21. Russo FY, Nguyen Y, De Seta D, et al. Meniett device in Meniere disease: randomized, double-blind, placebo-controlled multicenter trial. *Laryngoscope* 2017;127:470–475.
22. Syed MI, Ilan O, Leong AC, Pothier DD, Rutka JA. Ménière's syndrome or disease: time trends in management and quality of evidence over the last two decades. *Otol Neurotol* 2015;36:1309–1316.
23. Russo FY, De Seta D, Lahlou G, et al. Fluctuating hearing loss in the only hearing ear: cochlear implantation in the contralateral deaf side. *Otolaryngol Head Neck Surg* 2018;158:1101–1106.
24. Pullens B, Verschuur HP, van Benthem PP. Surgery for Ménière's disease. *Cochrane Database Syst Rev* 2013;(2):CD005395.
25. Paparella MM. Endaural labyrinthectomy. *Ear Nose Throat J* 2008;87:204.
26. Li CS, Lai JT. Evaluation of retrosigmoid vestibular neurectomy for intractable vertigo in Ménière's disease: an interdisciplinary review. *Acta Neurochir (Wien)* 2008;150:655–661.
27. Godlowski Z. Pathogenesis and management of Ménière's syndrome in terms of microcirculation. Pharmacologic decompression of the endolymphatic hydrops. *Angiology* 1965;16:644–650.
28. Friis M, Klauss O. A potential portal flow in the inner ear. *Laryngoscope* 2007;117:194–198.
29. Nadol JB, Adam JC, Kim JR. Degenerative changes in the organ of Corti and lateral cochlear wall in experimental endolymphatic hydrops and human Meniere's disease. *Acta Otolaryngol Suppl* 1995;519:47–59.
30. Ichimiya I, Adams JC, Kimura RS. Changes in immunostaining of cochleas with experimentally induced endolymphatic hydrops. *Ann Otol Rhinol Laryngol* 1994;103:457–468.
31. Friberg U, Rask-Andersen H. Vascular occlusion in the endolymphatic sac in Meniere's disease. *Ann Otol Rhinol Laryngol* 2002;11(3 pt 1):237–245.
32. Barbara M, Monini S, Chiappini I, Ronchetti F, Raffa S, Torrisi MR. Perisaccular vascular obstruction during an acute attack of Meniere's disease. *Mediterr J Otol* 2007;3:40–46.
33. Zamboni P. The big idea: iron-dependent inflammation in venous disease and proposed parallels in multiple sclerosis. *J R Soc Med* 2006;99:589–593.
34. Lee BB, Bergan J, Gloviczki, et al. Diagnosis and treatment of venous malformations Consensus Document of the International Union of Phlebology (IUP)—2009. *Int Angiol* 2009;28:434–451.
35. Lee BB, Baumgartner I, Berlien P, et al. Diagnosis and treatment of venous malformations. consensus document of the International Union of Phlebology (IUP): updated 2013. *Int Angiol* 2015;34:97–149.
36. Zamboni P, Galeotti R, Menegatti E, et al. A prospective open-label study of endovascular treatment of chronic cerebrospinal venous insufficiency. *J Vasc Surg* 2009;50:1348–1358.
37. Merchant SN, Adams JC, Nadol JB Jr. Pathophysiology of Meniere's syndrome: are symptoms caused by endolymphatic hydrops? *Otol Neurotol* 2005;26:74–81.
38. Alpini DC, Bavera PM, Hahn A, Mattei V. Chronic cerebrospinal venous insufficiency (CCSVI) in Meniere disease. Case or Cause? *ScienceMED* 2013;4:9–15.
39. Filipo R, Ciciariello F, Attanasio G, et al. Chronic cerebrospinal venous insufficiency in patients with Meniere's disease. *Eur Arch Otorhinolaryngol* 2013;272:77–82.
40. Bruno A, Califano I, Mastrangelo D, et al. Chronic cerebrospinal venous insufficiency in Meniere disease: diagnosis and treatment. *Otorhinolaryngologia* 2013;63:173.
41. Di Berardino F, Alpini DC, Bavera PM, et al. Chronic cerebrospinal venous insufficiency in Ménière disease. *Phlebology* 2015;30:274–279.
42. Bruno A, Califano L, Mastrangelo D, De Vizia M., Bernardo B, Salafia F. Chronic cerebrospinal venous insufficiency in Meniere's disease: diagnosis and treatment. *Veins Lymphatics* 2014;3:77–80.
43. Bruno A, Napolitano M, Califano L, et al. The prevalence of chronic cerebrospinal venous insufficiency in Meniere disease: 24-month follow-up after angioplasty. *J Vasc Interv Radiol* 2017;28:388–391.
44. Monzani D, Genovese E, Marrara A, et al. Validity of the Italian adaptation of the Tinnitus Handicap Inventory; focus on quality of life and psychological distress in tinnitus-sufferers. *Acta Otorhinolaryngol Ital* 2008; 28:126–134.
45. Nola G, Mostardini C, Salvi V, Ercolani AP, Ralli G. Validity of Italian adaptation of the Dizziness Handicap Inventory (DHI) and evaluation of the quality of life in patients with acute dizziness. *Acta Otorhinolaryngol Ital* 2010;30:190–197.
46. Zivadinov R, Bastianello S, Dake MD, et al. Recommendations for multimodal noninvasive and invasive screening for detection of extracranial venous abnormalities indicative of chronic cerebrospinal venous insufficiency: a position statement of the International Society for Neurovascular Disease. *J Vasc Interv Radiol* 2014;25:1785–1794
47. Ciccone MM, Galeandro AI, Scicchitano P, et al. Multigate quality Doppler profiles and morphological/hemodynamic alterations in multiple sclerosis patients. *Curr Neurovasc Res* 2012;9:120–127.
48. Mazzoni A. Vein of the vestibular aqueduct. *Ann Otol Rhinol Laryngol* 1979;88:759–767.
49. Nakai Y, Masutani H, Moriguchi M, Matsunaga K, Kato A, Maeda H. Microvasculature of normal and hydropic labyrinth. *Scanning Microsc* 1992;6:1097–1103.
50. Sisini F, Toro E, Gambaccini M, Zamboni P. The oscillating component of the internal jugular vein flow: the overlooked element of cerebral circulation. *Behav Neurol* 2015;2015:170756.
51. Adrion C, Fischer CS, Wagner J, Gürkov R, Mansmann U, Strupp M; BEMED study group. Efficacy and safety of betahistine treatment in patients with Meniere's disease: multicentre, double blind, randomized, placebo controlled, dose defining trial (BEMED trial). *BMJ* 2016;352: h6816.
52. Giaquinta A, Beggs CB, Veroux M, et al. Factors influencing the hemodynamic response to balloon angioplasty in the treatment of outflow anomalies of internal jugular veins. *J Vasc Surg Venous Lymphat Disord* 2017;5: 777–788.